Relationship between Alcoholics Extract of Citrollus Colocynthis and Rat Liver (Case Study: Iran-south East of Iran)

Rasool Khatibi
Department of Raneland and Watershed Managemennt, Facultyof Natural Resources
Uuniversity of Zabol, 98615, Zabol, Iran
Tel: 98-542-223-2600 E-mail: r_khatibi60@yahoo.com

Received: March 18, 2011 Accepted: April 8, 2011 Online Published: December 1, 2011
doi:10.5539/jas.v4n1p219 URL: http://dx.doi.org/10.5539/jas.v4n1p219

Abstract

There is an increasing tendency for traditional medicine in the world. Many people prefer to take herbal products instead of chemical medicines. However, over consumption of herbal medicines has led to many unpredictable side effects.One of these traditional medicines is Citrullus colocynthis, which is used by diabetic patients as an hypoglycemic agent, but it has been reported to cause gastrointestinal disorders after consumption in some patients.50 rats were randomly divided into five groups (4 experimental and 1 controls). In the experimental groups a single daily dose of alcoholic extract of Citrullus colocynthis (50, 100, 200, 400 g/kg) was administered intraperitonally. Normal saline was administered in control group. After two weeks, the rats were killed and the livers were removed and fixed with formalin (10%). Specimens were then processed and stained with H&E and Reticuline.The results indicated that there is a morphological change in liver cells including karyrrhexis, chromatolysis, and granulation of the cytoplasm. Additionally, collagen and reticular fibers were evident in liver parenchyma in high doses. Citrullus colocynthis can have toxic effects on liver cells which may induce hepatocyte necrosis and liver fibrosis. These effects were dose dependent. Further studies are necessary to clarify the issue.

Keywords: Citrullus colocynthis, Liver, Necrosis, Zabol

1. Introduction

Citrullus colocynthis (CCT) is traditionally used as an antidiabetic medication in tropical and subtropical countries (Diwan FH, 2000).This plant can induce insulinotropic (Nmila R, 2000) and mild immunostimulating effects (Bendeddou D, 2003).There is some evidence that it may induce side effects.The comparative toxicity of the alcoholic extract of CCT has been studied in seven insect species in which the adult honey bee was more affected (el-Naggar ME, 1989). Sheep which were fed fresh CCT fruits and leaves (0.2-10 g/kg) showed signs of weeks caused death in goats (Barri ME, 1983). The other side-effects of this plant are toxic acute colitis (Golfain D, 1989), reversible infertility (Chaturvedi M, 2003) and hepatotoxicity in rats (Barth A, 2002). These damages were sometimes enhanced with higher doses of CCT. As the liver is a sensitive organ and many substances including toxins accumulate in this organ and induce liver toxicity, therefore the aim of this project was to study the histopathological changes in the liver after ingestion of CCT in male rats.text

2. Materials and Methods

Citrullus colocynthis plants were collected in summer 2008 from the desert area near zabol, Iran. The plant was identified by Dr. Shokri in the Department of Biology at Mazandaran University Sari, Iran and a dry Voucher Specimen was desposited in the Herbarium of Zabol, Agriculture research center. The alcoholic extract of this plant was obtained using the percolation method; the yield was 4.6% of the crude plant. Fifty male rats, weighing 200-250 g were obtained from the Animal House of Shiraz Medical School and were maintained under standard conditions (light, temperature, humidity and free access to water and food). The rats were then selected and randomly divided into 5 groups (4 experimental and 1 control). In the experimental groups a single daily dose of the alcoholic extracts of Citrullus colocynthis (50, 100, 200, 400 mg/kg) was injected intraperitoneally. Each of the experimental groups received only one particular dose for the duration of 14 days. Normal saline was administered in the control group. After 14 days, the rats were sacrificed under deep anesthesia and their livers

were removed and fixed with 10% formalin. Specimens were processed routinely and sections with 5 micron thickness were prepared and stained with Hematoxiline- Eosine (H&E), Reticuline methods. The slides were studied by light microscopy by Knodell scoring system for assessing histological activity in asymptomatic chronic active hepatitis (Knodell RG, 2003) and the results were recorded. The results were analyzed using Chi-square and ANOVA tests. p-value less than 0.05 was considered statistically significant

3. Results

Intraperitoneal administration of Citrullus colocyn-this seeds to rats in the experimental groups caused some histopathological changes in their livers. Sections of the liver showed small hemorrhages in many lobules and congestion of central veins and sinusoids accompa-nied mild nonspecific inflammation with hepatocellular necrosis. Mixed neutrophil and lymphocyte infiltrate involving the parenchyma was observed but no bile duct injury. A morphological change in hepatocyte including karyorrehexis, chromatolysis and granulation of the cytoplasm was seen using H&E staining (Fig 1) espe-cially with doses of 200, 400 mg/kg. Collagen and reti-cular fiber were observed around more than the control group in parenchyma at a dose of 400 mg/kg using Reti-culine staining (Fig 2). All of these effects were dose dependent. These changes are shown in (Table 1).

4. Discussion

There is growing concern about the hepatotoxicity of herbal remedies (Larry D, 1997). Herbal hepatotoxicity has been recognized for many years, but new agents are constant-ly being identified (Chitturi S, 2000). Citrullus colocynthis extract was found free of hepatotoxic effect at concentrations up to 100 µg/mL (Barth A, 2002). But, higher concentrations seem to have some degree of hepatotoxicity. Male wistar rats that were fed diets containing 10% CCT ripe fruits showed body weight loss, inefficiency of feed utiliza- tion, diarrhea, ruffled hair and enterohepatonephrotoxic-ity (Adam SE, 2001). In this study, the effect of different concentra-tions of CCT on the liver was investigated. The results showed some histological changes in the nucleus and cytoplasm of hepatocytes. The changes observed in the nuclei included karyorrhexis and chromatolysis. The mechanism for these changes is not clear but other re-ports have showen that CCT has a damaging effect on different cells. The ethanol extract of CCT decreases the concentration of sialic acid in serum of mice. This de-crease is concomitant with an increase in the unmasking of galactose residues that is recognizable by macro-phages in apoptotic cell (Itzhaki O, 2003). Therefore; it seems that CCT by decreasing sialic acid induces cell degeneration. In addition, CCT causes an increase in neutrophils (Elawad AA, 1984) which confirms the above finding. Elevation of alkaline and acid phosphates is a useful marker for diseases of the liver such as liver cirrhosis (Israeli BA, 1986; Ryvniak VV, 1986). However, in some studies alkaline and acid phosphatase concentration was decreased by CCT (Chaturvedi M, 2003). So, it seems that CCT has probably no effect in causing liver cirrhosis. On the other hand, it is a well-known fact that in-flammation can be precursor of liver fibrosis. In our study, we observed scattered neutrophil and lympho-cytes in liver parenchyma. This phenomenon could po-tentially lead to liver cirrhosis. CCT has been shown to increased oxidative damage (Shivakumar Chitturi, 2000). On the other hand CCT extract has stimulated lipid peroxidation, H2O2 formation and has amplified chemi-luminescence in rat liver microsomes (Barth A, 2002). Therefore, it seems that a decrease in iron and an increase in lipid peroxidation induces the generation of free radicals which damages hepatocytes. In conclusion, CCT can have toxic effects on liver cells which may induce hepatocyte necrosis and liver fibrosis. However; more research is needed to clarify the issue.

References

Adam SE, Al Yahya MA, Al Farhan AH. (2001). Combined toxicity of Cassia senna and Citrullus colocynthis in rats. *Ven Hum Toxicol.*, 43(2):70-2.

Barri ME, Onsa TO, Elawad AA, Elsayed NY, Wasfi IA, Abdel Bari EM, Adam SE. (1983). Toxicity of five Sudanese plants to young ruminants. *J Comp Pathol.,* 93(4):559-675. http://dx.doi.org/10.1016/0021-9975(83)90063-4

Barth A, Muller D, Durrling K. (2002). In vitro investigation of a standardized dried extract of Citrullus colocynthis on liver toxicity in adult rats. *Exp Toxicol Pathol,* 54(3):223-30. http://dx.doi.org/10.1078/0940-2993-00252

Bendeddou D, Lalaoui K, Satta D. (2003). Immunostimulating activity of the hot water-soluble polysaccharide extracts of Anacyclus Pyrethrum, Alpinia galanga and Citrullus colocynthis. *J Ethnopharmacol.*, 88(2-3):155-60. http://dx.doi.org/10.1016/S0378-8741(03)00226-5

Chaturvedi M, Mali PC, Ansari AS. (2003). Induction of reversible antifertility with a crude ethanol extract of Citrullus colocynthis schrad fruit in male rats. *Pharmacology*, 68(1):38-48. http://dx.doi.org/10.1159/000068727

Chaturvedi M, Mali PC, Ansari AS. (2003). Induction of reversible antifertility with a crude ethanol extract of Citrullus colocynthis schrad fruit in male rats. *Pharmacology,* 68(1): 38-48. http://dx.doi.org/10.1159/000068727

Chitturi S, Farrell GC. (2000). Herbal hepatotoxicity: An expanding but poorly defined problem. *J Gastroenterol Hepatol.,* 15:1093-1099. http://dx.doi.org/10.1046/j.1440-1746.2000.02349.x

Diwan FH, Abdel-Hassan IA, Mohammed ST. (2000). Effect of Saponin on mortality and histopathological changes in mice. *Eastern Mediterranean Health Journal.,* 6(2-3):345-351.

Elawad AA, Abdel Bari EM, Mahmoud OM, Adam SE. (1984). The effect of Citrullus colocynthis on sheep. *Vet Hum Toxicol.*, 26(6):481-5.

el-Naggar ME, Abdel-Sattar MM, Mosallam SS. (1989). Toxicity of colocynithin and hydrated colocynithin from alcoholic extract of Citrullus colocynthis pulp. *J Egypt Soc Parasitol*, 19(1):179-85.

Golfain D, Lavergne A, Galian A, Chauveinc L, Prudhomme F. (1989). Peculiar acute colitis after ingestion of colocynth: a clinicopathological study of three cases. *Gut.*, 30(10):1412-8. http://dx.doi.org/10.1136/gut.30.10.1412

Israeli BA, Bogin E. (1986). Biochemical changes in liver, kidney and blood associated with common bile duct ligation. *Clin Chim Acta.,* 160(2):211-21.

Itzhaki O, Skutelsky E, Kaptzan T, Sinai, Michowitz M, Huszar M, Leibovici J. (2003). Ageing-apoptosis relation in murine spleen. *Mech Ageing Dev.,* 124(10- 12):999-1012.

Knodell RG, Ishak KG, Black WC, Chen TS, Graig R, Kaplowitz N, Kiernan TW, Wollman J. (2003). Formulation and application of a numerical scoring system for assessing histological activity in asymptomatic chronic active hepatitis. *J Hepatol.,* 38(4):382-6. http://dx.doi.org/10.1016/S0168-8278(03)00005-9

Larry D. (1997). Hepatotxicity of herbal remedies. *Hepatol.,* 26(1):47-51.

Nmila R, Gross R, Rchid H, Roye M, Manteghetti M, Petit P, Tijane Ribes G, Sauvaire Y. (2000). Insulinotropic effet of Citrullus colocynthis fruit extracts. *Planta Med.,* 66(5):418-23. http://dx.doi.org/10.1055/s-2000-8586

Ryvniak VV. (1986). Acid phosphatase distribution in the liver in cirrhosis. *Bull Eksp Biol Med.*, 101(3):363-5.

Shivakumar Chitturi, Geoffrey C Farrell. (2000). Herbal hepatotoxicity: An expanding but poorly defined problem. *J Gastroenterol Hepatol*, 15:1093-1099. http://dx.doi.org/10.1046/j.1440-1746.2000.02349.x

Table 1. The reaction of liver induced–CCT using H&E, PAS, staining between control and experimental groups

lesion / Groups	Hepatocyte necrosis H&E staining	fibrosis Inflammatory cells	Reticuline staining H&Estaining
Control	0	0	0
50 mg/kg	0	0	0
100 mg/kg	5	0	2
200 mg/kg	9	0	6
400 mg/kg	12	3	9

0: No reaction , 1-4: Minimal reaction , 5-8: Mild reaction , 9-12 : Moderate reaction, 13-18: Marked reaction

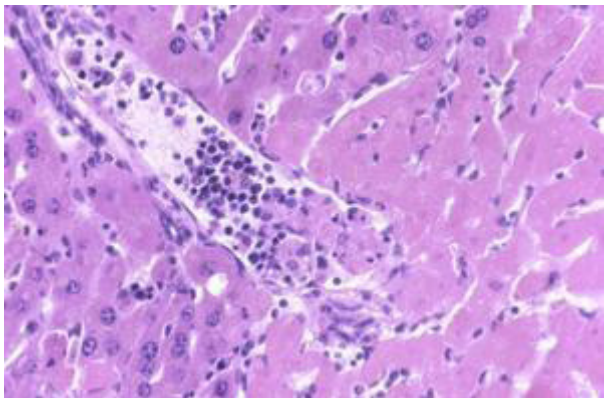

Figure 1. Liver cell necrosis in dose 400mg/kg with H&E staining(400×)

Figure 2. Reticular fiber in liver parenchyma in dose 400 mg/kg with Reticulin staining (100×)