

Topical Vasodilator Response is Significantly Higher in Skeletonized Internal Mammary Artery

Nida Butt¹, Sarah Hamid², Mujtaba Hussain¹, Ali Alam³, Hala Soomro¹, Tahreem Ahmad⁴, Madiha Ahmed², Ekta Golani¹, Janta Devi Ukrani¹, Faisal Iftikhar⁵, Rehmat Tufail⁵, Maha Begg², Samar Saleem⁴, Ayyaz Alam Sultan², Rohail Jameel¹, Waqas Shahnawaz⁶, Zohaib Farrukh⁷ & Asadullah Khan⁸

¹ Ziauddin Medical University, Karachi, Pakistan

² Dow University of Health Sciences, Karachi, Pakistan

³ Baqai Medical University, Karachi, Pakistan

⁴ Kind Edward Medical University, Lahore, Pakistan

⁵ Jinnah Medical and Dental College, Karachi, Pakistan

⁶ Aga Khan University, Karachi, Pakistan

⁷ Harbin Medical University, Heilongjiang Province, China

⁸ Department of Cardiac Surgery, Civil Hospital Karachi, Pakistan

Correspondence: Hala Soomro, Ziauddin University, Karachi, Pakistan. Plot 4/B, Shahrah-e-Ghalib, Block 6, Clifton, Karachi 75600, Pakistan. E-mail: hala.soomro@gmail.com

Received: April 28, 2016 Accepted: August 31, 2016 Online Published: September 28, 2016

doi:10.5539/gjhs.v9n4p279

URL: <http://dx.doi.org/10.5539/gjhs.v9n4p279>

Abstract

Aim of the Study: Coronary artery bypass graft surgery is the gold standard for the treatment of multi-vessel and left main coronary artery disease. However, there is considerable debate that whether left internal mammary artery (IMA) should be taken as pedicled or skeletonized. This study was conducted to assess the difference in blood flow after application of topical vasodilator in skeletonized and pedicled IMA.

Methods: In this study, each patient underwent either skeletonized (n=25) or pedicled IMA harvesting (n=25). The type of graft on each individual patient was decided randomly. Intra-operative variables such as conduit length and blood flow were measured by the surgeon himself. The length of the grafted IMA was carefully determined in-vivo, with the proximal and distal ends attached, from the first rib to IMA divergence. The IMA flow was measured on two separate occasions; before and after application of topical vasodilator. Known cases of subclavian artery stenosis and previous sternal radiation were excluded from the study.

Results: The blood flow before application of topical vasodilator was similar in both the groups ($P=0.227$). However, the flow was significantly less in pedicled than skeletonized IMA after application of vasodilator ($P<0.0001$). Similarly, the length of skeletonized graft was significantly higher than the length of pedicled graft ($P<0.0001$).

Conclusion: Our study signifies that skeletonization of IMA results in increased graft length and blood flow especially after the application of topical vasodilator. However, we recommend that long term clinical trials should be conducted to fully determine long term patency rates of skeletonized IMA.

Keywords: Skeletonized, pedicled, IMA, topical vasodilator

1. Introduction

Coronary artery bypass graft [CABG] surgery relieves angina symptoms and reduces mortality among ischemic heart disease patients [Coronary Artery Bypass Cooperative Study Group], (Hultgren, Peduzzi, Detre, & Takaro, 1985). It remains the gold standard for the treatment of multi-vessel and left main coronary artery disease (Yusuf et al., 1994). Since the beginning of 1980s, internal mammary artery [IMA] has been used for CABG (Milani et al., 2008). It is a well-known fact that IMA graft has the greatest long term patency rates of all the grafts. Its supremacy is due to its high resistance to atherosclerotic damage (Singh, Sosa, & Green, 1983; Sims, 1983), its own blood supply via the vasa vasorum, its own innervations, fewer myocytes in tunica media and a well-constructed internal

elastic lamina. Therefore, the patient can have a longer time without angina and the need for re-operations (Milani et al., 2008). Despite these advantages, there are some drawbacks of using IMA as bypass grafts. These include vasospasm and hypo perfusion in early post-CABG period especially when vasoactive medication is co-administered (Jones, Lattouf, & Weintraub, 1989; Paz et al., 2001). Use of IMA also results in reduced sternal blood flow (Carrier, Gregoire, Tronc, Cartier, Leclerc, & Pelletier, 1992) increased risk of wound infection (Loop et al., 1990) and increased and continuous post-operative pain (Eng J & Wells, 1991; Mailis, Umana, & Feindel, 2000; Mueller, Tinguely, Tevaearai, Revelly, Chiolero, & von Segesser, 2000).

The standard technique of harvesting known as pedicled grafting includes two satellite veins around the graft. Bilateral pedicled IMAs especially among diabetic patients have been reported to cause complications like sternal osteomyelitis (Milani et al., 2008). In many studies it has been reported that dissection of pedicled IMA can lead to sternal devascularization which can lead to higher incidence of infections (Milani et al., 2008). Considering this complication, dissection of IMA in skeletonized manner was proposed. In this method only the artery is harvested without its adjacent tissues. This method was devised to overcome the problems that had been associated with pedicled IMAs.

It has been suggested that skeletonized IMA helps to maintain sternal blood flow and therefore reduces the chances of sternal ischemia. This was confirmed by Cohen and his team later (Campo, 2003). It is also believed that skeletonized IMA could also lead to more distal anastomosis and increased graft length. Furthermore, it is believed to cause less post-operative pain (Wimmer-Greinecker et al., 1999). Due to these factors skeletonized IMA has started to gain popularity around the globe. However, long term effects of skeletonized IMA have not been established in regards of long term patency. Furthermore, skeletonized IMA also lacks the homeostatic milieu that is carried by the pedicled graft.

In order to assess the differences between skeletonized and pedicled grafts we conducted this study to evaluate variation in IMA flow, graft length and sternal dehiscence.

2. Materials and Methods

Patients undergoing non-emergent, isolated CABG surgery were included in this study. Single IMA graft was used in all the patients. Known cases of subclavian artery stenosis and previous sternal radiation were excluded from the study.

In this study, each patient underwent either skeletonized or pedicled IMA harvesting. The type of graft on each individual patient was decided randomly. During the course of the study patients were unaware whether they had received skeletonized or pedicled graft. Intra-operative variables such as conduit length and blood flow were measured by the surgeon himself.

The length of the grafted IMA was carefully determined in-vivo, with the proximal and distal ends attached, from the first rib to IMA divergence. After the graft was completely dissected along its whole span and before the division of its distal end, the mid segment was enclosed by a piece of sterilized silk suture. Constant stress was applied to both the ends of the suture. Another silk suture was used to follow the path of the IMA to determine its length from the first rib to the IMA bifurcation.

The IMA flow was measured on two separate occasions. The IMA was divided at the bifurcation and the free end was put into 30ml of empty syringe without the needle and the outlet was obstructed with the finger tip. Flow was allowed for 30 seconds and care was taken for the IMA not to be kinked. The IMA was sprayed with papaverine and wrapped in wet gauze. Temperature, Central Venous Pressure (CVP) and Mean Arterial Pressure (MAP) were noted at the time of flow measurements. After 10-15 minutes, second flow was measured in the same fashion provided strictly the same temperature, CVP and MAP.

Data was entered and analyzed in SPSS version 18.0. Descriptive statistics for continuous variables were presented as mean±standard deviation and frequencies along with percentages were displayed for categorical variables. Chi-square test was performed to compare categorical demographic, operative and post-operative variables between skeletonized and pedicled grafts. Mann-Whitney U test was executed to assess the same for continuous variables as normality test using Shapiro-Wilk's test revealed that these variables were skewed. *P* value less than 0.05 was considered to show significant difference in variables between the two grafts.

3. Results

A total of 50 patients were included in the study. Half of the patients underwent skeletonized grafting while the other half underwent pedicled grafting. Among them 31 (62%) were males. Most of the patients had O +ve blood group (n=28, 56%). Twenty three (46%) had a history of smoking, 26 (52%) were betel nut chewers, 22 (44%) had

a history of hypertension and 30 (60%) were diabetics. The mean Body surface area was 1.74 ± 0.034 m² and the mean ejection fraction was $46.82 \pm 6.09\%$. The distributions of these demographic factors were statistically similar for skeletonized and pedicled grafts except diabetic status ($P=0.004$) and body surface area ($P=0.042$) (Table 1). These factors were then set as confounding factors in later analyses for operative variables.

Table 1. Comparison of pre-operative variables between the two groups

		Skeletonized	Pedicled	<i>P</i> value
Gender	Male	14 (45.2%)	17 (54.8%)	0.382
	female	11 (57.9%)	8 (42.1%)	
Blood Group	A+	2 (100%)	0 (0%)	0.777
	A-	1 (100%)	0 (0%)	
	B+	5 (35.7%)	9 (64.3%)	
	AB+	2 (40%)	3 (60%)	
	O+	15 (53.6%)	13 (46.4%)	
Smoking	yes	11 (47.8%)	12 (52.2%)	0.258
	no	14 (51.9%)	13 (48.1%)	
Betel Nut	yes	11 (42.3%)	15 (57.7%)	0.569
	no	14 (58.3%)	10 (41.7%)	
Hypertension	yes	12 (54.5%)	10 (45.5%)	0.004
	no	13 (46.4%)	15 (53.6%)	
Diabetes	yes	20 (66.7%)	10 (33.3%)	0.042
	no	5 (25%)	15 (75%)	
Body Surface Area/ m ²		1.72±0.037	1.74±0.027	0.094
Ejection Fraction(%)		45.6±5.26	48.04±6.69	

Table 2. Comparison of intra-operative variables between the two groups

	Skeletonized	Pedicled	<i>P</i> value
Anastomosis	4.12±0.93	3.72±0.74	0.112
Length/cm	16.1±0.70	12.9±0.80	<0.0001
Blood flow before papaverine ml/minute	16.6±5.95	14.2±4.08	0.227
Blood flow after papaverine ml/minute	39.6±12.8	19.1±3.96	<0.0001

Table 3. Comparison of post-operative variables between the two groups

	Skeletonized	Pediced	P value
Hospital stay	8.36±0.95	8.32±0.99	0.943
Wound	0 (0%)	0 (0%)	>0.9999
Myocardial infarction	0 (0%)	0 (0%)	>0.9999
Stroke	0 (0%)	0 (0%)	>0.9999
Mortality	0 (0%)	0 (0%)	>0.9999

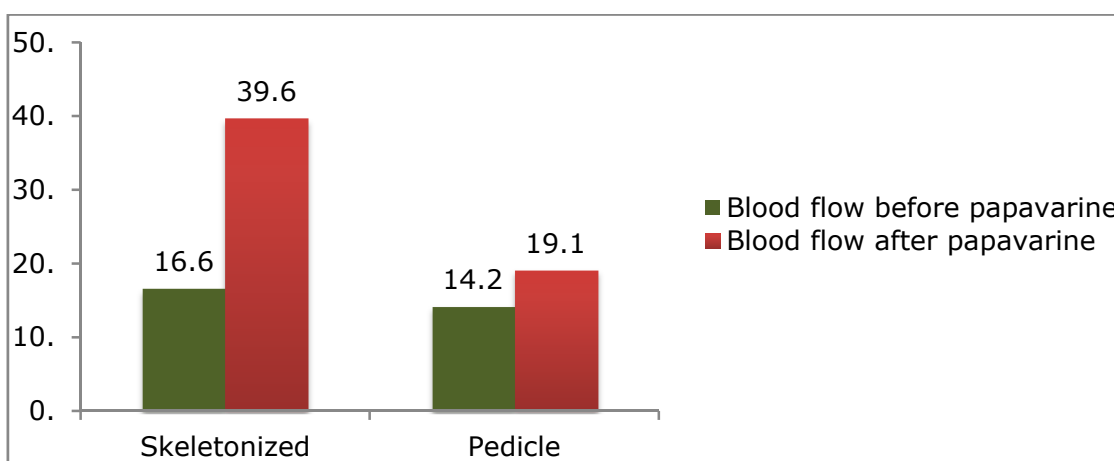


Figure 1. Mean Blood Flow Before and after application of Papaverine: P value<0.001 by Repeated Measure ANOVA

The average number of anastomosis was 3.92±0.85 while the mean length of grafts was 14.5±1.78 cm. The blood flow before papaverine was 15.4±5.19 ml/minute and after papaverine, it increased up to 29.34±13.99 ml/minute. The average hospital stay was 8.34±0.96 days. Comparing the operative and post-operative variables between skeletonized and pedicled grafted patients, the mean length of skeletonized graft was significantly higher than pedicled graft (P<0.0001). The mean blood flow before papaverine was similar in both groups (P=0.227). However, the flow was significantly less in pedicled than skeletonized IMA after application of papaverine (P<0.0001) (Table 2).

Repeated Measure ANOVA showed significant rise in blood flow after papaverine in both the groups (P<0.001) (Figure 1). Additionally, the operative variables were also compared between two groups while confounding the effect of diabetic status and body surface area. After confounding the effect of these two variables, analysis revealed that the length of graft and blood flow after application of papaverine were still significantly different in both the groups. None of the patient developed sternal wound infection, myocardial infarction or stroke during the procedure. The duration of hospital stay was significantly same for both the groups (P=0.943) (Table 3).

4. Discussion

Many studies over the past few decades have established that IMA is the best conduit choice for CABG due to its long lasting patency and long term survival (Wendler, Tscholl, Huang & Schäfers, 1999). However, there is significant dispute regarding the optimal harvesting technique for this conduit. In this study we compare the length of graft and blood flow in skeletonized and pedicled harvest of IMA. One of the main reasons provided by cardiac surgeons worldwide for choosing skeletonized IMA is that it provides greater length and increased blood flow (Pevni et al., 2001). Therefore we conducted this study to test the hypothesis that skeletonization increases graft length and blood flow especially after the application of papaverine.

The major baseline variables like smoking status, betel nut consumption, hypertension, gender and ejection

fraction were all insignificant between the 2 groups. This allowed fair comparison of operative variables between skeletonized and pedicled groups. Although there was a significant difference in the proportion of diabetics in the 2 groups, diabetic status was set as a confounding factor for analysis of operative variables. In our study neither myocardial infarction nor sternal wound infection occurred in either group. However, it is widely believed that skeletonized graft results in decreased incidence of sternal infections and other chest complications because skeletonization increases microcirculation and perfusion to the sternum (Hirose, Amano, Takanashi, & Takahashi, 2003).

The results of present study indicate that blood flow in skeletonized group was significantly higher than in pedicled group after application of papaverine. This is consistent with another study which also showed that blood flow in the 2 groups before papaverine injection was not significantly different but however after papaverine injection, skeletonized group had a much greater increase in blood flow (Pevni et al., 2001). Castro et al. also concluded in their study that skeletonization of IMA results in increased blood flow especially after application of a vasodilator (Castro, Dussin, Wender, Barbosa, & Saadi, 2005). Takami and Ina also showed in their study that skeletonization increases mean blood flow (Takami & Ina, 2002). Thus, we can say that our results help to strengthen the basic assumption that skeletonization does increase blood flow especially after the application of a topical vasodilator. This increase in blood flow in skeletonized grafts may be attributed to increased conduit caliber for anastomosis (Takami & Ina, 2002).

Furthermore, our results indicate that skeletonization of IMA grafts leads to a significantly increased length of the conduit. This is consistent with previous studies (Deja et al., 1999) that have also demonstrated an increment of up to 2.5 cm in skeletonized grafts. The mean length (16.1 cm) of skeletonized graft in our study was very similar to the mean length (18.3 cm) of skeletonized graft in another study done by Boodhwani et al. (Boodhwani, Lam, Nathan, Mesana, Ruel, & Zeng, 2006) Kandemir et al. also highlighted that skeletonization is associated with increased length of the conduit (15.7 +/- 0.4 cm in pedicled group versus 19.0 +/- 0.6 cm in skeletonized group; $P=0.001$) (Kandemir, Buyukates, Gun, Turan, & Tokmakoglu, 2007). The small variation that is obtained in lengths of these grafts among different studies may be due to skeletonization technique, vasodilator use and preferences in selection of patients. Increased conduit length may have great significance in the surgery outcome as it allows easy revascularization distally (Deja et al., 1999) and composite grafting. Moreover, quality and diameter of graft can effortlessly be determined by clear visual examination. Skeletonization of the graft also allows easy construction of sequential anastomosis, as supported by Cunningham (Cunningham, Mohammad, Fardin, & Meek, 1992). Our experience in this study also confirms the technical ease with which skeletonized grafts can be used for construction of multiple sequential anastomoses.

It is a well known fact that skeletonized grafts lead to better early and mid term patency rates. This is supported by a study conducted by Sauvage et al in which 150 patients, who underwent 3-vessel revascularization using skeletonization technique, had a patency rate of 85% at 7.4 years (Sauvage, Rosenfeld, Roby, Gartman, Hammond & Fisher, 2003). In this study (Sauvage, Rosenfeld, Roby, Gartman, Hammond, & Fisher, 2003). It was also concluded that IMA grafts for triple vessel revascularization offer outstanding results and are suitable for all categories of patients. However, our study did not measure mid or long term patency rates as we did not do follow up. Our study had another limitation due to scarce facilities in our public hospital. Intra-luminal flow could not be measured in IMA through Doppler technique. Due to lack of Doppler facility, we could only measure free flow in a crude manner.

5. Conclusion

Our study signifies that skeletonization of IMA results in increased graft length and blood flow especially after the application of topical vasodilator. We believe that skeletonization has many advantages, as proven by our study, so cardiac surgeons should use this new surgical technique to potentially improve the quality of IMA. However, we recommend that long term clinical trials should be conducted to fully determine long term patency rates of skeletonized IMA.

Competing Interests Statement

The authors declare that there is no conflict of interests regarding the publication of this paper.

References

- Boodhwani, M., Lam, B. K., Nathan, H. J., Mesana, T. G., Ruel, M., Zeng, W., ... Rubens, F. D. (2006). Skeletonized internal thoracic artery harvest reduces pain and dysesthesia and improves sternal perfusion after coronary artery bypass surgery: a randomized, double-blind, within-patient comparison. *Circulation*, *114*(8), 766-73. <http://dx.doi.org/10.1161/CIRCULATIONAHA.106.615427>

- Carrier, M., Gregoire, J., Tronc, F., Cartier, R., Leclerc, Y., & Pelletier, L. C. (1992). Effect of internal mammary artery dissection on sternal vascularization. *Ann Thorac Surg*, 53(1), 115-9. [http://dx.doi.org/10.1016/0003-4975\(92\)90768-Y](http://dx.doi.org/10.1016/0003-4975(92)90768-Y)
- Castro, G. P., Dussin, L. H., Wender, O. B., Barbosa, G. V., & Saadi, E. K. (2005). Comparative analysis of the flows of left internal thoracic artery grafts dissected in the pedicled versus skeletonized manner for myocardial revascularization surgery. *Arq Bras Cardiol*, 84(3), 261-6. <http://dx.doi.org/10.1590/S0066-782X2005000300013>
- Cunningham, J. M., Mohammad, A. G., Fardin, R., & Meek, R. A. (1992). Considerations in the skeletonization technique of internal thoracic artery dissection. *Ann Thorac Surg*, 54(5), 947-51. [http://dx.doi.org/10.1016/0003-4975\(92\)90656-O](http://dx.doi.org/10.1016/0003-4975(92)90656-O)
- Deja, M. A., Wos, S., Golba, K. S., Zurek, P., Domaradzki, W., Bachowski, R., ... Spyt, T. J. (1999). Intraoperative and laboratory evaluation of skeletonized versus pedicled internal thoracic artery. *Ann Thorac Surg*, 68(6), 2164-8. [http://dx.doi.org/10.1016/S0003-4975\(99\)00820-6](http://dx.doi.org/10.1016/S0003-4975(99)00820-6)
- Del Campo, C. (2003). Pedicled or Skeletonized? A Review of the Internal Thoracic Artery Graft. *Tex Heart Inst J*, 30(3), 170-5.
- Eng, J., & Wells, F. C. (1991). Morbidity following coronary artery revascularisation with the internal mammary artery. *Int J Cardiol*, 30(1), 55-9. [http://dx.doi.org/10.1016/0167-5273\(91\)90124-8](http://dx.doi.org/10.1016/0167-5273(91)90124-8)
- Hirose, H., Amano, A., Takanashi, S., & Takahashi, A. (2003). Skeletonized bilateral internal mammary artery grafting for patients with diabetes. *Interact Cardiovasc Thorac Surg*, 2(3), 287-92. [http://dx.doi.org/10.1016/S1569-9293\(03\)00046-X](http://dx.doi.org/10.1016/S1569-9293(03)00046-X)
- Hultgren, H.N., Peduzzi, P., Detre, K., & Takaro, T. (1985). The 5 year effect of bypass surgery on relief of angina and exercise performance. *Circulation*, 72(6), 79-83.
- Jones, E. L., Lattouf, O. M., & Weintraub, W. S. (1989). Catastrophic consequences of internal mammary artery hypoperfusion. *J Thorac Cardiovasc Surg*, 98(5), 902-7.
- Kandemir, O., Buyukates, M., Gun, B. D., Turan, S. A., & Tokmakoglu, H. (2007). Intraoperative and histochemical comparison of the skeletonized and pedicled internal thoracic artery. *Heart Surg Forum*, 10(2), 158-61. <http://dx.doi.org/10.1532/HSF98.20061196>
- Loop, F. D., Lytle, B. W., Cosgrove, D. M., Mahfood, S., McHenry, M. C., Goormastic, M., ... Taylor, P. C. (1990). Sternal wound complications after isolated coronary artery bypass grafting: Early and late mortality, morbidity, and cost of care. *Ann Thorac Surg*, 49(2), 179-86. [http://dx.doi.org/10.1016/0003-4975\(90\)90136-T](http://dx.doi.org/10.1016/0003-4975(90)90136-T)
- Mailis, A., Umana, M., & Feindel, C. M. (2000). Anterior intercostal nerve damage after coronary artery bypass graft surgery with use of internal thoracic artery graft. *Ann Thorac Surg*, 69(5), 1455-8. [http://dx.doi.org/10.1016/S0003-4975\(00\)01186-3](http://dx.doi.org/10.1016/S0003-4975(00)01186-3)
- Milani, R., Brofman, P. R., Guimarães, M., Barboza, L., Tchaick, R. M., Meister Filho, H., ... Maia, F. (2008). Double skeletonized internal thoracic artery vs. double conventional internal thoracic artery in diabetic patients submitted to OPCAB. *Rev Bras Cir Cardiovasc*, 23(3), 351-7. <http://dx.doi.org/10.1590/S0102-76382008000300011>
- Mueller, X. M., Tinguely, F., Tevaearai, H. T., Revelly, J. P., Chiolero, R., & von Segesser, L. K. (2000). Pain pattern and left internal mammary artery grafting. *Ann Thorac Surg*, 70(6), 2045-9. [http://dx.doi.org/10.1016/S0003-4975\(00\)01947-0](http://dx.doi.org/10.1016/S0003-4975(00)01947-0)
- Paz, Y., Gurevitch, J., Frolkis, I., Shapira, I., Pevni, D., Kramer, A., ... Mohr, R. (2001). Vasoactive response of different parts of human internal thoracic artery to isosorbide-dinitrate and nitroglycerin: An in-vitro study. *Eur J Cardiothorac Surg*, 19(3), 254-9. [http://dx.doi.org/10.1016/S1010-7940\(01\)00589-9](http://dx.doi.org/10.1016/S1010-7940(01)00589-9)
- Pevni, D., Kramer, A., Paz, Y., Lev-Run, O., Locker, C., Matsa, M., ... Mohr, R. (2001). Composite arterial grafting with double skeletonized internal thoracic arteries. *Eur J Cardiothorac Surg*, 20(2), 299-304. [http://dx.doi.org/10.1016/S1010-7940\(01\)00832-6](http://dx.doi.org/10.1016/S1010-7940(01)00832-6)
- Sauvage, L. R., Rosenfeld, J. G., Roby, P. V., Gartman, D. M., Hammond, W. P., & Fisher, L. D. (2003). Internal thoracic artery grafts for the entire heart at a mean of 12 years. *Ann Thorac Surg*, 75(2), 501-4. [http://dx.doi.org/10.1016/S0003-4975\(02\)04344-8](http://dx.doi.org/10.1016/S0003-4975(02)04344-8)

- Sims, F. H. (1983). A comparison of coronary and internal mammary arteries and implications of the results in the etiology of arteriosclerosis. *Am Heart J*, *105*(4), 560–6. [http://dx.doi.org/10.1016/0002-8703\(83\)90478-7](http://dx.doi.org/10.1016/0002-8703(83)90478-7)
- Singh, R. N., Sosa, J. A., & Green, G. E. (1983). Long-term fate of the internal mammary artery and saphenous vein grafts. *J Thorac Cardiovasc Surg*, *86*(3), 359-63.
- Takami, Y., & Ina, H. (2002). Effects of skeletonization on intraoperative flow and anastomosis diameter of internal thoracic arteries in coronary artery bypass grafting. *Ann Thorac Surg*, *73*(5), 1441-5. [http://dx.doi.org/10.1016/S0003-4975\(02\)03501-4](http://dx.doi.org/10.1016/S0003-4975(02)03501-4)
- The Veterans Administration Coronary Artery Bypass Surgery Cooperative Study Group. (1984). Eleven-year survival in the Veterans Administration randomized trial of coronary bypass surgery for stable angina. *N Engl J Med*, *311*(21), 1333-9. <http://dx.doi.org/10.1056/NEJM198411223112102>
- Wendler, O., Tscholl, D., Huang, Q., & Schäfers, H. J. (1999). Free flow capacity of skeletonized versus pedicled internal thoracic artery grafts in coronary artery bypass grafts. *Eur J Cardiothorac Surg*, *15*(3), 247-50. [http://dx.doi.org/10.1016/S1010-7940\(99\)00012-3](http://dx.doi.org/10.1016/S1010-7940(99)00012-3)
- Wimmer-Greinecker, G., Yosseef-Hakimi, M., Rinne, T., Buhl, R., Matheis, G., Martens, S., ... Moritz, A. (1999). Effect of internal thoracic artery preparation on blood loss, lung function, and pain. *Ann Thorac Surg*, *67*(4), 1078-82. [http://dx.doi.org/10.1016/S0003-4975\(99\)00161-7](http://dx.doi.org/10.1016/S0003-4975(99)00161-7)
- Yusuf, S., Zucker, D., Peduzzi, P., Fisher, L. D., Takaro, T., Kennedy, J. W., ... Chalmers, T. C. (1994). Effect of coronary artery bypass graft surgery on survival: overview of 10-year results from randomised trials by the Coronary Artery Bypass Graft Surgery Trialists Collaboration. *Lancet*, *344*(8922), 563-70. [http://dx.doi.org/10.1016/S0140-6736\(94\)91963-1](http://dx.doi.org/10.1016/S0140-6736(94)91963-1)

Copyrights

Copyright for this article is retained by the author(s), with first publication rights granted to the journal.

This is an open-access article distributed under the terms and conditions of the Creative Commons Attribution license (<http://creativecommons.org/licenses/by/4.0/>).